

Evaluation of Foveal Avascular Zone and Macular Vessel Density in Patients with Systemic Hypertension Using Optical Coherence Tomography Angiography

Maha Mohamed Abd El Fatah Ebraheim, Elham Abd El Azeem Mohamed,
Osama Mohamed Kamal, Hamdy Ahmed El Gazar, Taher Kamel Eleiwa

Department of Ophthalmology, Faculty of Medicine – Benha University, Egypt

*Corresponding author: Maha Mohamed Abd El Fatah, Mobile: (+20) 01026827241, E-Mail: maha.abdelfatah5519@yahoo.com

ABSTRACT

Background: Hypertension (HTN) affects cardiovascular, renal and neurological systems. The poorly controlled blood pressure may also cause structural and functional retinal damage. **Objective:** To assess changes in foveal avascular zone (FAZ) and macular vessel density using Optical Coherence Tomography Angiography (OCTA) in hypertensive patients. **Patients and Methods:** This case control observational study was performed on 120 eyes, divided into 3 groups. Group A: 40 eyes of 26 patients with HTN for more than 10 years, group B: 40 eyes of 22 patients with HTN less than 10 years, and group C: 40 eyes of 20 normal subjects with completely normal ophthalmological examination. All participants underwent OCTA.

Results: There was no significant variation in age, gender or FAZ between the three studied groups. Superficial capillary plexuses in parafovea, parafovea superior hemi, parafovea inferior hemi, perifovea, perifovea superior hemi, and perifovea inferior hemi were considerably higher in group C than in group A ($p = 0.002, 0.001, 0.011, 0.014, 0.041, \text{ and } 0.002$, respectively) and group B ($p < 0.001$). Deep capillary plexuses in parafovea, parafovea superior hemi, parafovea inferior hemi, perifovea, perifovea superior hemi, and perifovea inferior hemi were considerably higher in group C than in group A ($p < 0.001$), and group B ($p = 0.004, 0.004, 0.003, 0.002, 0.001, \text{ and } 0.003$, respectively). No significant difference were observed in the studied parameters between group A and B.

Conclusion: Eyes of HTN patients have lower macular vessel densities (superficial and deep) compared to those of healthy controls. The duration and control of hypertension didn't account any substantial differences between the two groups of hypertensive patients.

Keywords: FAZ; OCTA; HTN; Macular Vessel Density.

INTRODUCTION

Systemic hypertension increases risk of ischemic heart diseases, ischemic brain disorders and renal failure ⁽¹⁾. The prevalence of hypertension was estimated up to 59% in Egypt ⁽²⁾. It is characterized by structural and functional abnormalities in the microcirculation, including microvascular rarefaction and diminished circulatory efficiency, which eventually result in organ failure ⁽³⁾.

In HTN patients, elevated systemic arterial pressure is related to anatomical and functional retinal abnormalities. Arteriolar narrowing, arteriovenous nicking, retinal hemorrhage and optic disc swelling are examples of retinal injury ⁽⁴⁾.

Forty four percent of those evaluated for hypertension-related issues developed retinopathy ⁽⁵⁾. Retinal hypoperfusion was also seen in hypertensive individuals with inadequate blood pressure (BP) management ⁽⁶⁾.

Before permanent organ damage develops, imaging and clinical tests can identify these changes in hypertensive individuals ⁽⁷⁾. Consequently, retinal microvascular changes may be an effective predictor of HTN-related organ damage and a sign that hypertensive individuals require adequate hypertension control ⁽⁸⁾.

One of the techniques that analyses retinal microvasculature with high resolution is optical coherence tomography angiography (OCTA) with no need for dye injection ⁽⁹⁾.

The OCTA is being used to assess several retinal vascular diseases, including diabetic retinopathy and choroid neovascularization ⁽¹⁰⁾. Numerous studies have examined OCTA-derived data like region, vessel density (VD) and foveal avascular zone (FAZ) ^(11,12).

The FAZ is a capillary-free zone in the center of the macula, and its measurement has an important role for the diagnosis and treatment of a lot of retinal diseases ^(13,14).

Tan et al. ⁽¹⁵⁾ recent meta-analysis had been done to analyze macular vessel densities (SVD, DVD) and foveal avascular area in hypertensive patients. It revealed lower SVD and DVD and larger FAZ than control group.

This study investigated FAZ and macular VD changes using OCTA in systemic HTN patients, and test whether the duration and control of hypertension could affect the studied parameters or not.

PATIENTS AND METHODS

This case control study was carried out on 120 eyes of 68 patients recruited from Ophthalmology and Internal medicine Outpatient clinics at Benha University Hospitals.

Cases were divided into three groups: Group A consists of 40 eyes of 26 patients with HTN for over a decade. Group B: 40 eyes of 22 patients with HTN for less than 10 years. Group C: (control group): 40 eyes of 20 normal people having an ophthalmological examination that was fully normal.

Inclusion criteria:

- Patients with HTN (Groups A & B).
- Good candidates for OCTA imaging (no media opacity).
- No posterior segment pathology.
- Refractive error (between +4 and -4 D).
- No chronic uveitis.
- No history of glaucoma, retinopathy, retinal therapy, or other intraocular surgical intervention.
- Not on other medications affecting the retina.
- No other systemic diseases that affect retina.

Exclusion criteria:

- People who refuse to give a consent.
- Any posterior segment pathology.
- Refractive error (>+4 or <-4 D).
- Axial length (<23.6 mm) or (>25.5 mm).
- Chronic uveitis.
- History of glaucoma, retinopathy, retinal therapy, or other intraocular surgical intervention.
- Other systemic diseases that affect retina, or other medications that may affect retina vasculature as lipid lowering agents.

All patients underwent a comprehensive history and ocular examination, which included the following: pupillary reaction, best corrected visual acuity (BCVA) using Snellen's chart testing, refraction,

anterior segment examination by slit lamp, intraocular pressure measurement using an applanation tonometer, and fundus examination using +20D lens (for retinal periphery) and +90D lens (biomicroscopy for posterior pole).

Imaging:

OCTA was subsequently performed on each participant's macula using the AngioVue OCTA system (AngioVue: Optovue, Inc., USA). The retinochoroidal sublayers vasculature are visualized through motion contrast and a split-spectrum amplitude-decorrelation angiography (SSADA) algorithm⁽¹⁶⁾. The FAZ was automatically estimated utilizing the application's non flow area characteristics.

At the parafoveal area, thickness of inner retina and overall thickness of the retina were also measured. The FAZ is the zone without blood vessels within the fovea. On OCTA images, this area of the fovea lacks significant flow signals that distinguish regions with high and no flow from the retinal vasculature⁽¹⁷⁾.

The following parameters were assessed in superficial and deep capillary plexuses; whole image, whole image superior hemi, and whole image inferior hemi, fovea, parafovea, parafovea superior hemi, parafovea inferior hemi, perifovea, perifovea superior hemi, and perifovea inferior hemi (figure 1).

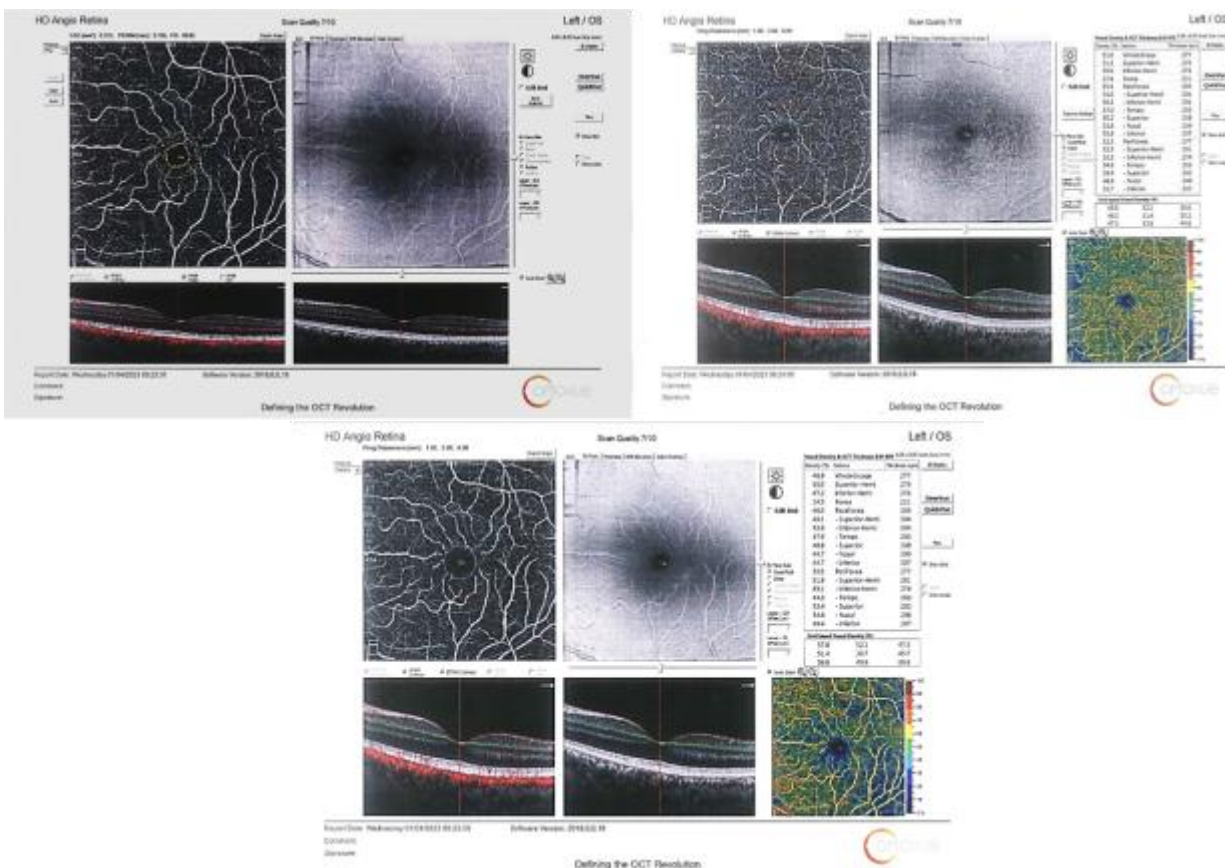


Figure (1): A combined exported OCTA images captured from the left eye of a study subject showing the foveal avascular zone (left), superficial (right) and deep (middle) capillary plexuses vessel density regional parameters.

Ethical approval:

Benha University’s Faculty of Medicine Ethical Review Board Committee accepted the research instruments and methods (MS 34-8-2021). Informed consent was signed by all subjects involved. The Declaration of Helsinki for human beings, which is the international medical association’s code of ethics, was followed during the conduct of this study.

Statistical analysis

IBM SPSS Statistics for Windows, Version 25.0, was used to analyze the acquired data (Armonk, New York: IBM Corporation 2005). For normally distributed data, in order to compare continuous variables between the three studied groups, we used

ANOVA test, whereas the Kruskal-Wallis test was performed for non-normally distributed data. If significant difference was present, appropriate post hoc testing was carried out.

The categorical variables were analyzed using the Chi-Square test. Significance of the obtained results was judged at the (0.05) level at CI 95%. P value < 0.05 was considered significant.

RESULTS

This case control study involved 80 eyes from 48 hypertension patients and 40 eyes from 20 control participants. Demographic, baseline and clinical characteristics of patients were summarized in (Table 1).

Table (1): Baseline characteristics of the patients in the studied groups

		Group A (n =26)	Group B (n =22)	Group C (n =20)	p value
Age (years)	Mean ± SD	56.54 ± 4.58	52.41 ± 9.21	52.9 ± 3.96	0.053
	Range	50 - 65	30 - 62	48 - 60	
Gender	Male	12 (46.2%)	10 (45.5%)	10 (50%)	0.567
	Female	14 (53.8%)	12 (54.5%)	10 (50%)	
Duration of HTN	Mean ± SD	16 ± 6.03	4.26 ± 3.16	-	<0.001*
	Range	11 - 30	0.75 - 10	-	
BCVA	6/6	17 (43%)	19 (48%)	32 (80%)	0.001* P1: 0.822 P2: 0.001* P3: 0.005*
	6/9	23 (58%)	21 (53%)	8 (20%)	
FAZ (mm³)	Mean ± SD	0.3 ± 0.06	0.3 ± 0.07	0.3 ± 0.07	0.144
		HTN patients		Controls	p value
FAZ (mm³)	Mean ± SD	0.298 ± 0.056		0.303 ± 0.062	0.237

HTN: Hypertension, SD: Standard deviation, BCVA: Best corrected visual acuity, FAZ: Foveal avascular zone * Statistically significant as p value ≤0.05, P1: Significance between groups A and B, P2: Significance between groups A and C, P3: Significance between groups B and C.

HTN duration was considerably higher in group A compared to group B (p <0.001) but there was insignificant difference between the two groups whether their HTN was controlled or not. There was insignificant difference in FAZ between the studied groups. Regarding the superficial and deep capillary plexuses vessel densities, all the studied parameters were significantly higher in group C than group A and group B, but there was insignificant difference between groups A and B (p<0.05, p<0.01, Tables 2 and 3, respectively).

Table (2): Superficial capillary plexuses whole image and fovea in the studied groups

		Group A (n =40)	Group B (n =40)	Group C (n =40)	p value
Whole image	Mean ± SD	48.27 ± 3.36	46.88 ± 3.99	50.58 ± 4.03	<0.001* P1: 0.751 P2: 0.014* P3: <0.001*
	Range	39.1 - 55.5	37.4 - 52.5	41.9 - 57	
Whole image superior hemi	Mean ± SD	48.41 ± 3.2	46.92 ± 4.1	50.62 ± 4.32	<0.001* P1: 0.092 P2: 0.025* P3: <0.001*
	Range	40 - 54.6	38 - 53.3	41.3 - 56.3	
Whole image inferior hemi	Mean ± SD	48.14 ± 3.69	46.82 ± 4.13	50.54 ± 3.88	<0.001* P1: 0.136 P2: 0.014* P3: <0.001*
	Range	38.4 - 56.4	36.6 - 51.8	42.6 - 57.7	
Fovea	Mean ± SD	18.66 ± 6.39	18.21 ± 5.64	19.68 ± 6.67	0.561
	Range	6.8 - 29.4	2.6 - 33.3	3.8 - 34.2	
Parafovea	Mean ± SD	50.09 ± 3.69	48.14 ± 5.85	52.86 ± 5.21	<0.001* P1: 1.000 P2: 0.002* P3: <0.001*
	Range	41.3 - 55.9	34.6 - 56.9	36 - 59.2	
Parafovea superior hemi	Mean ± SD	50.34 ± 3.25	48.28 ± 5.59	53.21 ± 5.21	<0.001* P1: 0.845 P2: 0.001* P3: <0.001*
	Range	45.2 - 55.8	37.4 - 55.9	33.6 - 59.7	
Parafovea inferior hemi	Mean ± SD	49.86 ± 4.75	47.99 ± 6.47	52.54 ± 5.43	<0.001* P1: 1.000 P2: 0.011* P3: <0.001*
	Range	36.7 - 56.2	29.2 - 57.9	38.5 - 59.1	
Perifovea	Mean ± SD	49.1 ± 3.69	47.63 ± 4.3	51.52 ± 4.01	<0.001* P1: 0.747 P2: 0.014* P3: <0.001*
	Range	39.5 - 58.2	36.6 - 53.5	41.9 - 57.6	
Perifovea superior hemi	Mean ± SD	49.36 ± 3.65	47.61 ± 4.53	51.45 ± 4.51	<0.001* P1: 0.511 P2: 0.041* P3: <0.001*
	Range	39.5 - 57.7	37.6 - 54.1	41 - 57.5	
Perifovea inferior hemi	Mean ± SD	48.82 ± 3.96	47.63 ± 4.37	51.6 ± 3.66	<0.001* P1: 1.000 P2: 0.002* P3: <0.001*
	Range	39.5 - 58.8	35.5 - 53.4	42.8 - 58.2	

SD: Standard deviation, * Statistically significant as p value ≤0.05, P1: Significance between groups A and B, P2: Significance between groups A and C, P3: Significance between groups B and C.

Table (3): Deep capillary plexuses whole image and fovea in the studied groups

		Group A (n =40)	Group B (n =40)	Group C (n =40)	p value
Whole image	Mean ± SD	45.58 ± 5.3	46.89 ± 7.45	53.42 ± 8.92	<0.001* P1: 0.943
	Range	35.1 - 54.7	27.4 - 60.3	33.9 - 64.7	P2: <0.001* P3: <0.001*
Whole image superior hemi	Mean ± SD	46.01 ± 5.63	46.73 ± 7.51	53.73 ± 8.82	<0.001* P1: 1.000
	Range	34.5 - 54.6	25.6 - 60.1	33.6 - 65.6	P2: <0.001* P3: <0.001*
Whole image inferior hemi	Mean ± SD	45.17 ± 5.19	47.07 ± 7.55	53.1 ± 9.2	<0.001* P1: 0.394
	Range	35.7 - 54.8	27.4 - 60.6	34.1 - 63.9	P2: <0.001* P3: 0.004*
Fovea	Mean ± SD	34.46 ± 7.42	33.21 ± 7.37	35.61 ± 8.06	0.647
	Range	20.4 - 52.4	7 - 49.5	19.4 - 50.4	
Parafovea	Mean ± SD	50.99 ± 3.58	52.85 ± 6.46	57.52 ± 6.12	<0.001* P1: 0.115
	Range	42.5 - 59.5	29.7 - 62.9	42.1 - 65.4	P2: <0.001* P3: 0.004*
Parafovea superior hemi	Mean ± SD	51.77 ± 3.18	53.11 ± 6.66	57.75 ± 5.91	<0.001* P1: 0.322
	Range	44.1 - 60	29.8 - 63.4	43.7 - 66.1	P2: <0.001* P3: 0.004*
Parafovea inferior hemi	Mean ± SD	50.23 ± 4.32	52.57 ± 6.44	57.29 ± 6.4	<0.001* P1: 0.094
	Range	40.9 - 58.9	29.7 - 62.3	40.4 - 65.4	P2: <0.001* P3: 0.003*
Perifovea	Mean ± SD	46.3 ± 6.03	47.75 ± 8.44	54.72 ± 9.7	<0.001* P1: 0.884
	Range	34.5 - 54.8	24.3 - 62.5	33.9 - 66.3	P2: <0.001* P3: 0.002*
Perifovea superior hemi	Mean ± SD	46.8 ± 6.57	47.8 ± 8.34	55.1 ± 9.5	<0.001* P1: 0.511
	Range	33.8 - 55.2	22.8 - 62	34.3 - 67.1	P2: <0.001* P3: <0.001*
Perifovea inferior hemi	Mean ± SD	45.81 ± 5.94	47.71 ± 8.82	54.29 ± 9.98	<0.001* P1: 0.487
	Range	33.6 - 55.1	26 - 63.1	32.8 - 66	P2: <0.001* P3: 0.003*

SD: Standard deviation, * Statistically significant as p value ≤0.05, P1: Significance between groups A and B, P2: Significance between groups A and C, P3: Significance between groups B and C.

Factorial analysis of the hypertension groups according to the duration and control of the hypertension did not reveal any statistical significance.

DISCUSSION

In our study, we report that vessel densities of the retinal sublayers were significantly lower in HTN than controls, while the FAZ size did not differ between all groups. Also, we report that the duration and control of hypertension did not account for any difference between the two hypertensive groups.

According to FAZ, **Sun et al.**⁽¹⁷⁾ and **Niro et al.**⁽¹⁸⁾ found no substantial difference between HTN patients and control group, similar to our results. On the other hand, **Hua et al.**⁽¹⁹⁾, **Lee et al.**⁽²⁰⁾ and **Lim et al.**⁽²¹⁾ reported larger FAZ area in HTN groups. This contrast might be explained by variations in patient clinical characteristics and potential recall bias of the study design.

Regarding the superficial capillary plexuses VD parameters, we found that they were substantially greater in group C than group A and B. Although, there was no significant statistical difference between groups A and B. In agreement with our findings, **Hua et al.**⁽¹⁹⁾ found that superficial plexus vessel densities and capillary density were substantially altered in hypertensive patients with free retinal examination. Also, they reported no significant statistical difference between hypertensive patients regarding duration of hypertension. **Sun et al.**⁽¹⁷⁾, **Lee et al.**⁽²⁰⁾ and **Lim et al.**⁽²¹⁾, reported that the superficial and deep macular densities and perfusion density in the HTN group were significantly reduced.

The association between hypertension and macular capillary density is unclear. The decrease in superficial plexus vascular density seen in our study may have resulted from a constriction of the retinal microvasculature owing to the extended duration of HTN, past, transitory blood pressure variations, and present blood pressure. Retinal microvasculature constriction may induce an increase in microcirculation resistance that leads to a decrease in microvascular circulation to retina; with subsequent decline in VD⁽²¹⁾. Previous research revealed that decreased retinal VD in HTN is the consequence of vascular constriction due to an increase in vascular resistance, which may inhibit blood flow⁽²²⁾.

We found that control of HTN did not account any significant difference between hypertension groups. However, **Takayama et al.**⁽²³⁾ reported that patients with controlled hypertension had stable superficial retinal vasculature. Furthermore, the foveal vascular density showed no difference between the three groups. **Chua et al.**⁽⁶⁾, compared the superficial vascular parameters (SVP) and deep vascular parameters (DVP) and found that patients with poorly controlled blood pressure had lower retinal capillary density at the DVP.

Regarding the deep capillary plexuses VD parameters, we found that they were substantially greater in group C than group A and B. Although there

was no significant statistical difference between groups A and B.

According to **Sun et al.**⁽¹⁷⁾ and **Chua et al.**⁽⁶⁾, deep parafoveal, deep (foveal + parafoveal) flow densities, parafoveal inner retina thickness and parafoveal region thickness substantially decreased in hypertensive group. In contrast, **Hua et al.**⁽¹⁹⁾, found no significant difference between the studied groups at deep plexus vascular density. **Niro et al.**⁽¹⁸⁾ reported no statistically significant difference between the HTN and control groups in superficial and deep vascular density in foveal and parafoveal areas. Patients with hypertensive retinopathy were excluded from these two reports, which demonstrated that patients with controlled hypertension had stable superficial retinal microcirculation.

This variable reports might be owing to the technological limitations of OCT-A devices. For instance, the slow blood flow beyond a minimal threshold detected by the device may appear as a vascular rarefaction or even a non-perfusion area on OCT-A images. Furthermore, some optical properties such as the eye's axial length and myopia can generate noise and cause the vascular network to appear unnaturally thick due to the larger area being scanned as reported by **Yang et al.**⁽²⁴⁾.

This study is not without limitations. First, the case control nature of our study did not allow to assess temporal changes in the studied parameters. Second, we did not evaluate other recognized contributors to ischemia-induced retinal damage including hyperlipidemia and smoking. Third, some individuals with chronic HTN may have had retinal damage as a result of past hypertensive events. Fourth, it is difficult to use this strategy to eyes that have axial length (<23.6mm) or (>25.5mm) due to the fact that this study only addressed normal axial length. Finally, this research had a limited sample size and relied on patient's recollections of their medical history, which might be prone to recall bias. Hence, further prospective study with longer duration and larger number of participants is needed to address the aforementioned limitations and replicate our findings.

CONCLUSION

In comparison to healthy eyes, the macular vessel densities (superficial and deep) in eyes of individuals with systemic HTN were significantly reduced. Duration and control of HTN did not account any substantial difference between the two groups of HTN patients.

Funding: None.

Conflict of Interest: None to declare.

REFERENCES

1. **Buus N, Mathiassen O, Fenger-Grøn M et al. (2013):** Small artery structure during antihypertensive therapy is an independent predictor of cardiovascular

- events in essential hypertension. *J Hypertens*, 31(4):791–7.
2. **Reda A, Ragy H, Saeed K et al. (2021):** A semi-systematic review on hypertension and dyslipidemia care in Egypt—highlighting evidence gaps and recommendations for better patient outcomes. *J Egypt Public Health Assoc.*, 96(1):1–14.
 3. **Feihl F, Liaudet L, Waeber B (2009):** The macrocirculation and microcirculation of hypertension. *Curr Hypertens Rep.*, 11(3):182–9.
 4. **FraserBell S, Symes R, Vaze A (2017):** Hypertensive eye disease: a review. *Clin Experiment Ophthalmol.*, 45(1):45–53.
 5. **Kolman S, Van Sijl A, Van Der Sluijs F et al. (2017):** Consideration of hypertensive retinopathy as an important end-organ damage in patients with hypertension. *J Hum Hypertens*, 31(2):121–5.
 6. **Chua J, Chin C, Hong J et al. (2019):** Impact of hypertension on retinal capillary microvasculature using optical coherence tomographic angiography. *J Hypertens*, 37(3):572–77.
 7. **Ding J, Wai K, McGeechan K et al. (2014):** Retinal vascular caliber and the development of hypertension: a meta-analysis of individual participant data. *J Hypertens*, 32(2):207–11.
 8. **Konstantinidis L, Guex-Crosier Y (2016):** Hypertension and the eye. *Curr Opin Ophthalmol.*, 27(6):514–21.
 9. **Spaide R, Fujimoto J, Waheed N et al. (2018):** Optical coherence tomography angiography. *Prog Retin Eye Res.*, 64:1–55.
 10. **Scarinci F, Picconi F, Giorno P et al. (2018):** Deep capillary plexus impairment in patients with type 1 diabetes mellitus with no signs of diabetic retinopathy revealed using optical coherence tomography angiography. *Acta Ophthalmol.*, 96(2): 264–5.
 11. **Zhang W, Kang L, Zhang Y et al. (2020):** Quantitative analysis of retinal and choroidal microvascular parameters using optical coherence tomography angiography in children with nephrotic syndrome: a pilot study. *Graefe's Arch Clin Exp Ophthalmol.*, 258(2):289–96.
 12. **Uji A, Balasubramanian S, Lei J et al. (2017):** Impact of multiple en face image averaging on quantitative assessment from optical coherence tomography angiography images. *Ophthalmology*, 124(7):944–52.
 13. **Kashani A, Chen C, Gahm J et al. (2017):** Optical coherence tomography angiography: a comprehensive review of current methods and clinical applications. *Prog Retin Eye Res.*, 60:66–100.
 14. **Kumagai K, Furukawa M, Suetsugu T et al. (2018):** Foveal avascular zone area after internal limiting membrane peeling for epiretinal membrane and macular hole compared with that of fellow eyes and healthy controls. *Retina*, 38(9):1786–94.
 15. **Tan W, Yao X, Le T et al. (2021):** The application of optical coherence tomography angiography in systemic hypertension: a meta-analysis. *Front Med.*, 8:778330. doi: 10.3389/fmed.2021.778330..
 16. **Chalam K, Sambhav K (2016):** Optical coherence tomography angiography in retinal diseases. *J Ophthalmic Vis Res.*, 11(1):84–92.
 17. **Sun C, Ladores C, Hong J et al. (2020):** Systemic hypertension associated retinal microvascular changes can be detected with optical coherence tomography angiography. *Sci Rep.*, 10(1):1–9.
 18. **Niro A, Sborgia G, Lampignano L et al. (2022):** Association of Neuroretinal Thinning and Microvascular Changes with Hypertension in an Older Population in Southern Italy. *J Clin Med.*, 11(4):1098. <https://doi.org/10.3390/jcm11041098>
 19. **Hua D, Xu Y, Zeng X et al. (2020):** Use of optical coherence tomography angiography for assessment of microvascular changes in the macula and optic nerve head in hypertensive patients without hypertensive retinopathy. *Microvasc Res.*, 129:103969. doi: 10.1016/j.mvr.2019.103969.
 20. **Lee W, Park J, Won Y et al. (2019):** Retinal microvascular change in hypertension as measured by optical coherence tomography angiography. *Sci Rep.*, 9(1):1–7.
 21. **Lim H Bin, Lee M, Park J et al. (2019):** Changes in ganglion cell–inner plexiform layer thickness and retinal microvasculature in hypertension: an optical coherence tomography angiography study. *Am J Ophthalmol.*, 199:167–76.
 22. **Kannenkeril D, Harazny J, Bosch A et al. (2018):** Retinal vascular resistance in arterial hypertension. *Blood Press.*, 27(2):82–7.
 23. **Takayama K, Kaneko H, Ito Y et al. (2018):** Novel classification of early-stage systemic hypertensive changes in human retina based on OCTA measurement of choriocapillaris. *Sci Rep.*, 8(1): 1–13.
 24. **Yang Y, Wang J, Jiang H et al. (2016):** Retinal microvasculature alteration in high myopia. *Invest Ophthalmol Vis Sci.*, 57(14): 6020–30.